

## Efficacy of Unfocused Medium-Intensity Extracorporeal Shock Wave Therapy (MI-ESWT) for Plantar Fasciitis

Ashraf Fansa, MD<sup>1</sup>, Alec J. Talsania, BA<sup>2</sup>, John G. Kennedy, MD, FRCS<sup>3</sup>, Martin J. O'Malley, MD<sup>4,5</sup>

<sup>1</sup> NYU Langone Foot and Ankle Fellow, New York, NY

<sup>2</sup> Lewis Katz School of Medicine at Temple University, Philadelphia, PA

<sup>3</sup> Professor and Chief, Foot and Ankle Department, NYU Langone, New York, NY

<sup>4</sup> Hospital for Special Surgery, New York, NY

<sup>5</sup> Associate Professor of Orthopedics, Weill Medical College of Cornell University, New York, NY

### ARTICLE INFO

Level of Clinical Evidence: 4

#### Keywords:

foot and ankle outcome score

heel pain

OrthoGold 100™ shock wave device

plantar fascia

shock wave therapy

visual assessment scale

### ABSTRACT

Extracorporeal shock wave therapy (ESWT) is a promising treatment for plantar fasciitis (PF), however, treatment results have varied due to inconsistencies among types of shock wave treatment and devices used. This retrospective chart review includes patients who underwent ESWT using the OrthoGold 100™ shock wave device (MTS, Konstanz, Germany) for PF between January, 2013 and September, 2018. There were 108 patients (119 heels) identified, with a mean age of  $51.7 \pm 16.5$  (Range 21-83) years. Patients were treated weekly for 3 weeks, with 2000 impulses per session at an energy flux density between 0.10 and 0.17 mJ/mm<sup>2</sup>. Mean follow-up duration was  $11.5 \pm 9.7$  (Range 3-51) months. Mean pre-ESWT pain visual assessment scale improved from  $6.7 \pm 1.7$  to  $2.6 \pm 2.7$  ( $p < .001$ ). The Foot and Ankle Outcome Score subscales: pain, function of daily living, function of sports and recreational activities and quality of life domains improved from  $53.7 \pm 14.9$  to  $75.7 \pm 16.7$  ( $p < .001$ ), from  $38 \pm 15.2$  to  $71.8 \pm 23$  ( $p < .001$ ), from  $55.8 \pm 16.4$  to  $71.4 \pm 18$  ( $p < .001$ ), from  $42.4 \pm 21.5$  to  $59.4 \pm 20.3$  ( $p < .001$ ) and from  $44.9 \pm 16.4$  to  $69 \pm 23.9$  ( $p < .001$ ), respectively. Eighty-eight (81.5%) patients were satisfied with the procedure at final follow-up. Treatment of PF with unfocused shock waves was well tolerated and led to significant pain reduction, functional improvement, and patient satisfaction.

© 2020 by the American College of Foot and Ankle Surgeons. All rights reserved.

Plantar fasciitis (PF) is the most common cause of heel pain, estimated to affect 10% of people during their lifetime and accounting for more than 1 million office visits per year (1-5). PF most commonly presents from age 40 to 60, and risk factors include obesity, running, and decreased ankle dorsiflexion (4,6,7). Other factors associated with PF include pes planus, pes cavus, spondyloarthropathies, and a tight Achilles tendon (8). Patients with PF typically complain of pain upon first standing in the morning and are tender to palpation at the medial tubercle of the calcaneus (5,8). The majority of cases resolve with conservative therapy alone within 6 to 18 months (4,9). However, 10% of patients may develop chronic pain, significantly affecting quality of life and necessitating further intervention (10).

The diagnosis of PF is mostly clinical, supported by the characteristic pain localized at the medial tubercle of the calcaneus (9). Calcaneal spurs have been associated with PF and may be present on radiograph in 35% to 50% of patients, however their presence is not diagnostic and

is often regarded as an incidental finding (8,11,12). Ultrasound may be used to rule out other causes of foot pain and may show plantar fascia thickening (>4 mm), which has been reported in 47.3% of feet with PF (11). Magnetic resonance imaging (MRI) may also be obtained to confirm a diagnosis of PF or to rule out other pathology, however it may be normal in 20% of patients (13).

Available treatments for PF can be broadly divided into nonsurgical and surgical treatments. Nonsurgical modalities include rest, activity modification, ice massage, oral analgesics, strengthening and stretching exercises, orthotics, and splints (1,2). More invasive nonsurgical options include corticosteroid injections, Platelet-rich plasma (PRP) injections, dry needling, and botulinum toxin injections (2,14-16). About 5% to 10% of patients may fail nonsurgical treatment and go on to require surgical management, which includes plantar fasciotomy, neurotomy, neurolysis, calcaneal spur resection, and calcaneal decompression (9). Currently, endoscopic plantar fasciotomy is the authors' preferred surgical approach.

Extracorporeal shock wave therapy (ESWT) is an innovative modality that has been shown to be a promising technique in treating PF (17-22). Since its introduction to orthopedics, it has since been used to manage multiple orthopedic conditions, including lateral epicondylitis, calcifying tendinitis of the shoulder, and fracture nonunions (23-28). The

**Financial Disclosure:** None reported.

**Conflict of Interest:** None reported.

Address correspondence to: Martin J. O'Malley, MD, Weill Medical College of Cornell University, 1300 York Ave, New York, NY 10065.

E-mail address: [OMalleyM@hss.edu](mailto:OMalleyM@hss.edu) (M.J. O'Malley).

application of ESWT for treating PF was first described in 1995 (22). Since then, many have described the use of ESWT for treating PF, however the type of ESWT has been highly variable, potentially accounting for the lack of consensus on ESWT for PT (19,29-32).

There are variations in the mechanics of how a shock wave may be produced and delivered, and currently these differences are broken into the following categories: Focused, which includes electrohydraulic, electromagnetic and piezoelectric devices, and unfocused, which is limited to the electrohydraulic method, for reasons including physics and patents (33). It is noteworthy that radial acoustic pressure pulse devices, while unfocused, are not ESWT devices, as they produce a different wave form (34,35). Low-intensity electromagnetic and piezoelectric devices rely on focusing the energy produced down to a focal point where enough is condensed to cause a shock wave to form (36). Therefore, the shock wave is created within the tissue at a fixed focal length. Low-intensity electrohydraulic devices create a shock wave at the source inside the applicator head (37). If a focused applicator is used, then a second shock wave is produced within the tissue at the fixed focal length (36). With an unfocused electrohydraulic applicator, the energy dispersal pattern is wide, with no secondary shock wave, as there is no focal point (37). These unfocused electrohydraulically-produced shock waves trigger the same biologic responses as focused devices do, with the advantage of a much larger shock wave zone, increasing efficiency of the treatment and reducing risk by eliminating the energy concentrations which occur at focal points (37,38). In addition, the unfocused shock wave is much better tolerated by the patient and does not require local anesthesia or general anesthesia. The variability in type of shock wave is one of the main reasons that it remains poorly understood as a treatment modality.

An electrohydraulically-produced shock wave is an acoustic wave that transmits energy, generated from an underwater high voltage discharge that creates a transient pressure difference. (36) It is characterized by high peak pressures (>100 mpa), a rapid rise in pressure (<10 ns), and short duration (<10 ns) (39). This wave propagates through water and is transferred to the human body via a contact medium. The shock waves can be delivered in a focused or unfocused manner. Unfocused ESWT, are referred to as "Soft" waves. Once a shock wave is generated, it travels through water and is then transmitted into the body via an applicator with an ellipsoid reflector, with a combination of direct and reflected waves. Whenever the wave reaches an interface between different mediums, part of the wave is reflected, and part is transmitted. Although the exact mechanism of shock wave therapy is not understood, evidence suggests that the therapeutic effects of shock waves are induced by the release of energy at interfaces, which generates a cellular response via mechanotransduction, thereby enabling a cascade of biological effects (39-42). In essence, the shock wave provides the mechanical stimulus that is translated into biochemical signals via mechanotransduction. The proposed biologic effects include modulation of the inflammatory response, neovascularization, increased cell proliferation and collagen synthesis, resorption of calcifications, and downregulation of metalloproteinases (36,39,43).

One advantage to soft shock wave is that its maximum energy is exerted at the skin interface and is distributed in a wide pattern into tissue, allowing for treatment of a larger area (22). In contrast, hard shock waves deliver focused energy to a smaller focus that is localized subcutaneously (22). ESWT can be further separated to low- (energy flux density <0.1 mJ/mm<sup>2</sup>), medium- (energy flux density: 0.1-0.2 mJ/mm<sup>2</sup>), and high- (energy flux density ≥0.2 mJ/mm<sup>2</sup>) intensity treatments. One meta-analysis has previously suggested that medium-intensity ESWT (MI-ESWT) was more effective than control (20).

We were interested in determining if unfocused MI-ESWT was satisfactory in decreasing pain, and increasing function and quality of life in patients with PF. We hypothesized that pre-ESWT Foot and Ankle Outcome Score (FAOS) and Pain visual assessment scale (VAS) scores would

improve after unfocused MI-ESWT. Our primary aim was to measure change in Pain VAS scores, and our secondary aim was to measure change in FAOS scores. We undertook a retrospective chart review to compare pre-ESWT FAOS and Pain VAS scores.

## Patients/Materials and Methods

After obtaining approval from our institutional review board, we conducted a retrospective chart review of all patients whom underwent consecutive ESWT for the treatment of PF from January 2013 to September 2018. The initial search identified 124 patients from the Foot and Ankle registry and treated by senior authors (J.G.K., M.J.O.). Sixteen patients were excluded due to failure to satisfy our inclusion criteria. To be included, all patients had to satisfy the following criteria: Minimum age 18 years; Minimum follow-up duration 3 months; Clinical diagnosis of PF; Minimum duration of symptoms 3 months; No recent history of invasive treatments (Cutoff 3 months) such as corticosteroid injections, PRP injections or prolotherapy; No history of surgical plantar fascia release. All patients had undergone an initial period of conservative management of at least 3 months before receiving ESWT. This included one or more of the following modalities: physical therapy and stretching, night splints, orthotics, and non-steroidal anti-inflammatory drugs. The diagnosis of PF was made by 2 fellowship trained foot and ankle surgeons with more than 20 years of experience.

## Treatment Protocol

The unfocused shock waves were generated electrohydraulically with the OrthoGold 100™ shock wave device (MTS, Konstanz, Germany) (Fig. 1). The yellow applicator OP 155 delivering an unfocused shock wave was utilized (TRT, Woodstock, GA). Patients were initially given approximately 500 introductory impulses (starting at 0.06 and gradually increasing to 0.1) during which the energy flux density (EFD) was gradually increased to reach a comfortable and moderate intensity between 0.12 and 0.17 mJ/mm<sup>2</sup>. We considered it a successful treatment if they were able to get 2000 impulses at a level of 0.1 mJ/mm<sup>2</sup> or higher. After reaching the desired EFD patients received 2000 impulses per session, which was repeated on a weekly basis for 3 weeks. The applicator was placed over the point of maximal tenderness (Fig. 2). Local or regional anesthesia was not utilized.

The primary outcome was the amount of change in heel pain at final follow-up relative to preprocedure. This was measured on the 0-10 VAS of pain. Patient satisfaction with the procedure was also recorded. Patients were either satisfied with the procedure or not satisfied. Secondary outcome measures included the FAOS both preprocedure and at final follow-up.

Statistical analysis was performed by the SPSS software version 25 (SPSS Inc., Chicago, IL). The Paired-Samples *t* test was utilized to analyze the amount of change between pre and post-ESWT FAOS and pain VAS scores. The data was analyzed for normality of distribution by the Shapiro-Wilk test. Data that failed the normality of distribution test was further analyzed for statistically significant change by the Wilcoxon Signed-Rank test. For further analysis the patients were divided into 3 age groups (under 39 years; 40-59 years; 60 years and above). The amount of change in FAOS and Pain VAS scores between the age groups was analyzed for statistically significant differences using the One-Way ANOVA test. The Levene test was utilized to test for homogeneity of variance. Data sets that were not normally distributed were further analyzed with the Kruskal-Wallis H test. Independent-Samples *t* test was used to assess the difference between males and females regarding the amount of change between pre- and post-ESWT FAOS and Pain VAS scores. Significant difference was defined as *p* ≤ .05. All data is presented in mean ± standard deviation, unless otherwise stated.

## Results

Patient demographics, pre- and post-ESWT FAOS, VAS pain scores and patient satisfaction were collected from the charts of 108 patients (119 heels) who met our beforementioned inclusion criteria (Table 1). Of the 108 patients, 51 (47%) had right-sided heel pain, 46 (43%) had left-sided heel pain and 11 (10%) had bilateral heel pain. Mean age was 51.7 ± 16.5 (Range 21-83) years, males represented 43% (46/108) of the cohort and mean follow-up duration was 11.5 ± 9.7 (Range 3-51) months. Radiographs of the lateral foot were obtained for all patients and a spur was present in 32 (29.6%) patients. In the 53 patients that had an MRI, calcaneal edema was present in 28 (52.8%) patients and the PF thickness was >4 mm in 22 (41.5%) patients (Fig. 3).

The mean pre-ESWT pain VAS improved from 6.7 ± 1.7 to 2.6 ± 2.7 (*p* < .001) at final follow-up (Table 2). All five domains of the FAOS score improved significantly at final follow-up relative to pretreatment levels. The FAOS Symptoms, Pain, Function of Daily Living, Function of Sports and Recreational activities and Quality of Life domains improved from

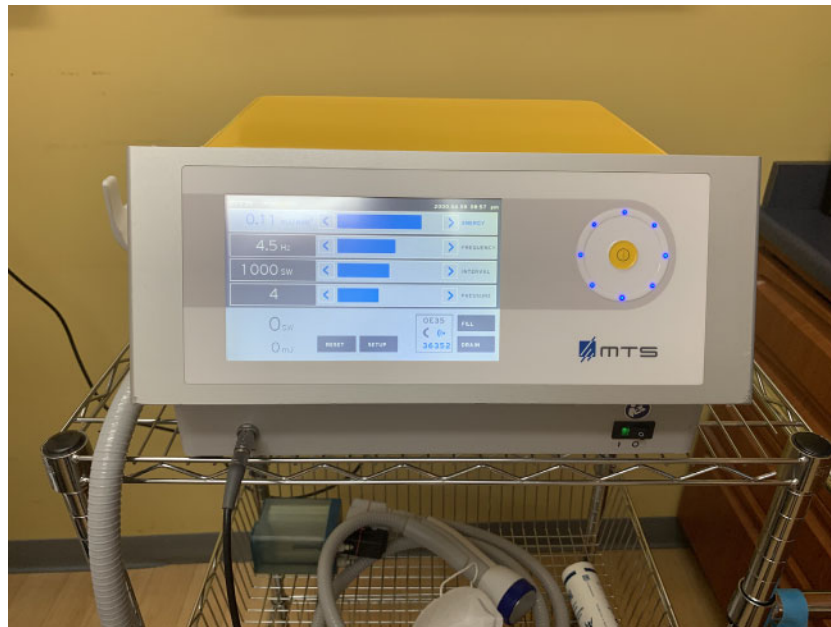

Fig. 1. OrthoGold 100™ shock wave device.

53.7 ± 14.9 to 75.7 ± 16.7 ( $p < .001$ ), from 38 ± 15.2 to 71.8 ± 23 ( $p < .001$ ), from 55.8 ± 16.4 to 71.4 ± 18 ( $p < .001$ ), from 42.4 ± 21.5 to 59.4 ± 20.3 ( $p < .001$ ) and from 44.9 ± 16.4 to 69 ± 23.9 ( $p < .001$ ), respectively (Table 2). Eighty-eight (81.5%) patients were satisfied with the procedure at final follow-up. The 20 patients who did not achieve pain relief following ESWT underwent a trial of local PRP injection. Six patients failed PRP and ended up with minimally invasive plantar fascia release surgery.

Patients were divided into 3 age groups to further investigate any associations between age and pain and functional outcomes. Twenty-six patients fell into the 18 to 39 years old age bracket, 41 were between 40 and 59 years, and the remaining 41 patients were 60 years

and older. No associations were observed between patient age and pain scores, FAOS scores or satisfaction.

### Discussion

The PF plays a major role in maintaining the arch of the foot and is subject to tensile stress with weight bearing and locomotion (7). The proximal portion that attaches to the calcaneus is composed of long fibers of fibrocartilaginous tissue that has been described as vascular, innervated, and metabolically active (7). The pathogenesis of PF is not well understood. One common theory is that repetitive microtrauma to the insertion point triggers inflammation, leading to degenerative

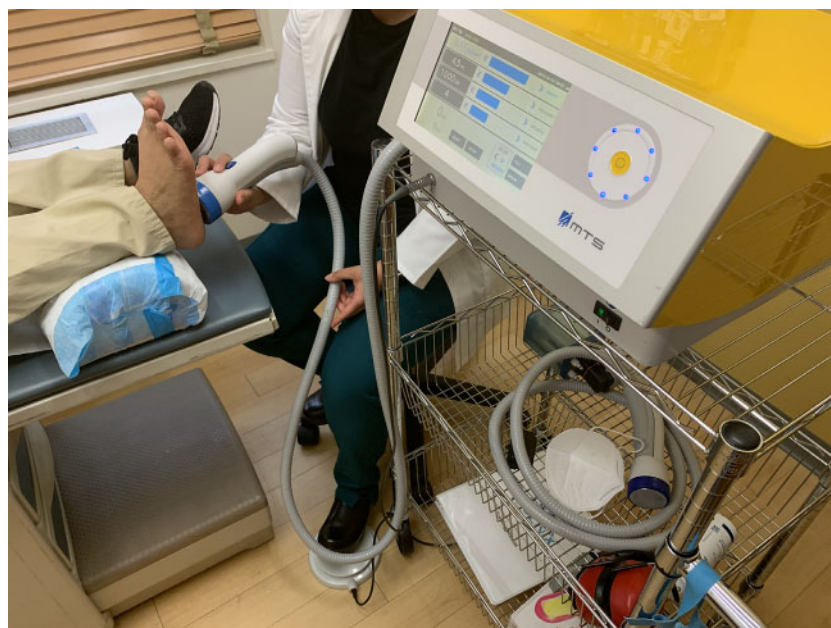

Fig. 2. Clinical picture of patient receiving treatment with OrthoGold 100™ shock wave device at point of maximal tenderness.

**Table 1**

A statistical description of the cohort (N = 119 heels in 108 patients)

Variable	Value
Number of patients (heels)	108 (119)
Age (years)	51.7 ± 16.5 (Range 21–83)
Gender	
Male	46 (43)
Female	62 (57)
Laterality	
Right	51 (47)
Left	46 (43)
Bilateral	11 (10)
Follow-up duration (months)	11.5 ± 9.7 (Range 3–51)
Patient satisfaction	88 (81.5)

Data presented as N (%), unless otherwise stated.

changes (8). Examination of pathologic PF tissue has shown disorganized and degenerating collagen fibers, angiofibroblastic hyperplasia, calcification, microtears, and matrix calcification (12,44).

The effects of shock waves in humans were first investigated in the 1960s, and was first used to treat kidney and gallbladder stones in the 1970s, as the shock waves carry sufficient energy to break up the calculi (45,46). Extracorporeal shock wave lithotripsy has remained a first-line treatment option for nephrolithiasis and ureterolithiasis since the 1980s (47). The use of shock wave therapy was first introduced in the field of orthopedics in 1991 for healing pseudarthroses, and its use in orthopedics has continued to expand (22,48).

The results from the present study demonstrate a 61% reduction in pain intensity on the VAS pain scale and a greater than 80% satisfaction rate with the procedure at final follow-up (Tables 1 and 2). Furthermore, all 5 domains of the FAOS demonstrated statistically significant improvements at final follow-up compared to pre-ESWT scores (Table 2). Our results are in agreement with previous studies in the literature supporting the effectiveness of ESWT for the treatment of PF (29–31,49). An elegant prospective, multicenter, double-blind, randomized, and placebo-controlled US Food and Drug Administration trial published by Gollwitzer et al. reports similar results from 250 patients (49). The authors generated focused shock waves electromagnetically with the DUOLITH® SD1 shock wave device (Storz Medical). The study group received 3 weekly sessions of 2000 focused pulses with an EFD of 0.25 mJ/mm<sup>2</sup>. Pain in the study group receiving ESWT was decreased by a mean of 54.5% at the 12 weeks timepoint following the last ESWT session which was significantly different than the placebo group. Similar to our treatment algorithm, patients in this study received a minimum of 2000 shocks weekly for 3

**Table 2**

Primary and secondary outcome results (N = 119 heels in 108 patients)

Variable	Pre-ESWT	Post-ESWT	p Value
Pain VAS	6.7 ± 1.7	2.6 ± 2.7	< .001
FAOS			
Symptoms	53.7 ± 14.9	75.7 ± 16.7	< .001
Pain	38 ± 15.2	71.8 ± 23	< .001
FDL	55.8 ± 16.4	71.4 ± 18	< .001
FSR	42.4 ± 21.5	59.4 ± 20.3	< .001
QOL	44.9 ± 16.4	69 ± 23.9	< .001

Abbreviations: FDL, function of daily living; FSR, function of sports and recreational activities; QOL, quality of life.

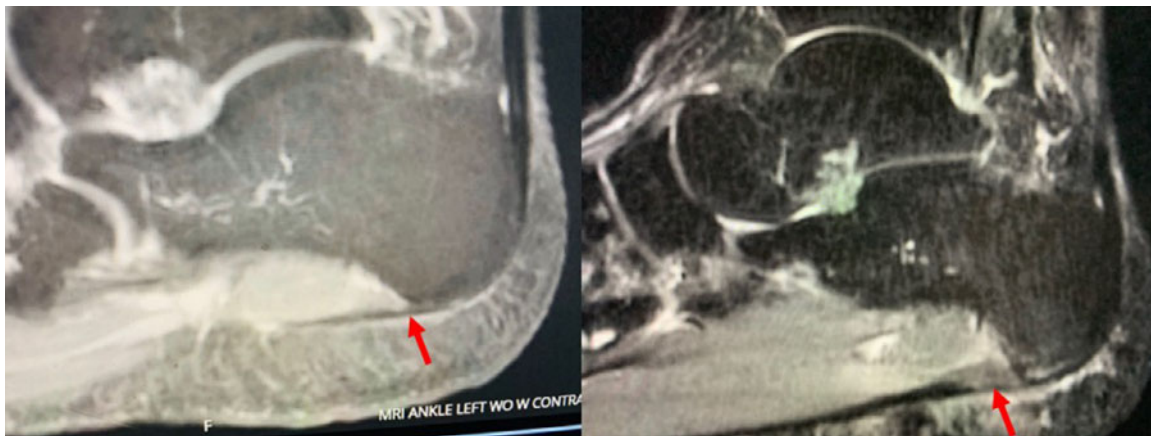
Data presented as mean ± standard deviation.

weeks with a high EFD. Unlike our study, the device utilized generates focused shock waves electromagnetically.

Purcell et al reported similar results in their study on both active and nonactive duty personnel (31). Pain decreased by a mean of 68% on the VAS pain scale at a mean follow-up duration of 42 ± 22 months. Similar to our study, they administered 2000 high energy shock waves to their patients. Unlike our study, however, almost all of their patients received only one session of ESWT. The authors do not mention the type or name of device used to deliver ESWT.

Lai et al compared ESWT to corticosteroid injection (CSI) in a randomized controlled trial on 97 patients at 12 weeks follow-up (30). The authors used the electrohydraulic Orthospect™ device (Medispec, Gaitersburg, MD). The study group received 1500 pulses per session for 2 sessions 2 weeks apart with an EFD of 0.29 mJ/mm<sup>2</sup>. At final follow-up, both ESWT and CSI groups showed significant reduction on the pain scale, from 6.23 ± 1.11 to 1.34 ± 1.24 and from 6.24 ± 1.1 to 2.98 ± 0.84, respectively. However, the amount of pain reduction in the ESWT group at final follow-up was significantly higher than the CSI group. Similar to our study, the ESWT treatment group received high energy shock waves, however, it was slightly less in total number of shocks delivered than our study.

In contrast to the above reported outcomes, Porter and Shadbolt compared ESWT to CSI and a placebo group in 144 patients in a prospective, randomized study over a period of 12 months (50). The authors state they used an electrohydraulic device. Patients received 1000 pulses weekly at an EFD of 0.08 mJ/mm<sup>2</sup> for 3 weeks. At 3 months follow-up, mean CSI pain scores were significantly better than ESWT, 1.48 (range 0–7) and 3.69 (range 0–8), respectively. However, at the 12 months follow-up time point, both CSI and ESWT had similar pain scores, 0.84 (range 0–7) and 0.84 (0–4), respectively. The inferior results of ESWT at



**Fig. 3.** A. Sagittal T1-weighted MRI demonstrating a normal black signal from plantar fascia. B. Sagittal fat-suppressed T2-weighted MRI of typical patient with plantar fasciitis, 3 months after onset of heel pain demonstrating marked thickening and high signal at origins of plantar fascia.

the 3 months timepoint could be attributed to low quantity and low-intensity shock waves (0.08 mJ/mm<sup>2</sup> for 1000 pulses only per session).

Cinar, Saxena, and Uygur compared ESWT to low-level laser therapy and a placebo control group in 63 patients with a follow-up duration of 3 months (51). The investigators used a radial pulse generator (EMS Swiss Dolor Clast) to deliver 2000 shocks weekly for 3 weeks at an EFD of 0.02 mJ/mm<sup>2</sup>. The authors report statistically significantly lower pain scores for the low-level laser therapy group versus the ESWT group at both the 3 weeks and 3 months timepoints. We believe the inferior results reported in this study, compared to what the current study reports, may be due to the use of a radial pulse generator, rather than a true ESWT. Additionally, the EFD was far lower than reported in the current study and previous studies that demonstrated success in pain reduction using ESWT.

It is critical to understand the heterogeneity in devices used for ESWT between various studies in order to make meaningful comparisons and create future treatment paradigms. Electrohydraulic devices generate pressure pulses that enjoy the beforementioned shock wave characteristics at the spark source and therefore can generate both focused and unfocused shock waves (52,53). On the other hand, both piezoelectric and electromagnetic devices only produce shock waves at the focal area, and therefore require wave focusing to generate true shock waves (52). Therefore, piezoelectric and electromagnetic dependent devices cannot produce true shock waves at low-amplitudes (34,54). However, electrohydraulic dependent devices are capable of generating true shock waves at low-, mid- and high-amplitude settings making them more reliable in that regards (34,54). This is an important point since the device and applicator utilized in our current study delivers an unfocused shock wave. Due to its capacity to produce true shock waves at lower amplitudes without focusing, treatment delivery with this applicator covers a wider area and tends to be less painful (53,55).

Ballistic devices, also referred to as Radial Shock Wave devices, while often incorrectly referred to as shock wave devices, do not generate shock waves according to the laws of physics but rather generate an acoustic pressure wave (34,35,56). The rise time of the generated impulses to reach peak pressures is too long (approximately 90 times longer) for the generated wave to be considered a shock wave. Therefore, ballistic devices are more appropriately named Radial Wave generating devices (56).

The present study has several limitations. As a retrospective study, we are unable to demonstrate the superiority of our treatment modality over another. In addition, as the study is retrospective in nature, it is subject to bias. Our study is also limited, as we did not include known risk factors for PF, including body mass index.

In conclusion, the results of our present study demonstrate the efficacy of unfocused shock waves for the treatment of PF in a mixed patient population presenting to an orthopedic clinic. Shock waves have shown to be effective in a variety of orthopedic conditions, but the variability in wave forms and treatment regimens have made it difficult to make meaningful conclusions. Unfocused shock waves delivered with an intensity of 0.10 to 0.17 mJ/mm<sup>2</sup> were well tolerated by patients and led to significant pain reduction, functional improvement and patient satisfaction. We propose that future studies report in more detail the type and brand of device utilized to deliver ESWT in order to better assess any discrepancies that might be related to type of shock wave generated. Future prospective randomized controlled studies assessing the efficacy of unfocused medium-intensity true shock waves for the treatment of PF are warranted.

## Acknowledgments

We would like to acknowledge Ken Lippe for sharing his expertise on shock wave devices.

## References

- Roxas M. Plantar fasciitis: diagnosis and therapeutic considerations. *Altern Med Rev* 2005;10:83–93.
- Goff JD, Crawford R. Diagnosis and treatment of plantar fasciitis. *Am Fam Physician* 2011;84:676–682.
- Crawford F, Thomson CE. Interventions for treating plantar heel pain. *Cochrane Database Syst Rev* 2003.
- Toomey EP. Plantar Heel Pain. *Foot Ankle Clin* 2009;14:229–245.
- Riddle DL, Schappert SM. Volume of ambulatory care visits and patterns of care for patients diagnosed with plantar fasciitis: A national study of medical doctors. *Foot Ankle Int* 2004;25:303–310.
- Riddle DL, Pulisic M, Pidcoe P, Johnson RE. Risk factors for plantar fasciitis: A matched case-control study. *J Bone Joint Surg Am* 2003;85:872–877.
- Gill LH. Plantar fasciitis: Diagnosis and conservative management. *J Am Acad Orthop Surg* 1997;5:109–117.
- Cutts S, Obi N, Pasapula C, Chan W. Plantar fasciitis. *Ann R Coll of Surg Engl* 2012;94:539–542.
- Wearing SC, Smeathers JE, Urry SR, Hennig EM, Hills AP. The pathomechanics of plantar fasciitis. *Sports Med* 2006;36:585–611.
- Irving DB, Cook JL, Young MA, Menz HB. Impact of chronic plantar heel pain on health-related quality of life. *J Am Podiatr Med Assoc* 2008;98:283–289.
- Menz H, Thomas M, Marshall M, et al. Coexistence of plantar calcaneal spurs and plantar fascial thickening in individuals with plantar heel pain. *Rheumatology (Oxford)* 2019;58:237–245.
- Williams SK, Brage M. Heel pain-plantar fasciitis and Achilles enthesopathy. *Clin Sports Med* 2004;23:123–144.
- Fazal MA, Tsekes D, Baloch I. Is there a role for MRI in plantar heel pain. *Foot Ankle Spec* 2018;11:242–245.
- Jain K, Murphy PN, Clough TM. Platelet rich plasma versus corticosteroid injection for plantar fasciitis: A comparative study. *Foot (Edinb)* 2015;25:235–237.
- Ahmad J, Ahmad SH, Jones K. Treatment of plantar fasciitis with Botulinum toxin. *Foot Ankle Int* 2017;38:1–7.
- Li H, Lv H, Lin T. Comparison of efficacy of eight treatments for plantar fasciitis: A network meta-analysis. *J Cell Physiol* 2018;234:860–870.
- Sun K, Zhou H, Jiang W. Extracorporeal shock wave therapy versus other therapeutic methods for chronic plantar fasciitis. *Foot Ankle Surg* 2020;26:33–38.
- Aqil A, Siddiqui MRS, Solan M, Redfern DJ, Gulati V, Cobb JP. Extracorporeal shock wave therapy is effective in treating chronic plantar fasciitis: A meta-analysis of RCTs. *Clin Orthop Relat Res* 2013;471:3645–3652.
- Wu CH, Lin YY, Chen WS, Wang TG. Sonoelastographic evaluation of plantar fascia after shock wave therapy for recalcitrant plantar fasciitis: A 12-month longitudinal follow-up study. *Sci Rep* 2020;10:2571.
- Wang YC, Chen SJ, Huang PJ, Huang HT, Cheng YM, Shih CL. Efficacy of different energy levels used in focused and radial extracorporeal shockwave therapy in the treatment of plantar fasciitis: A meta-analysis of randomized placebo-controlled trials. *J Clin Med* 2019;8:1497.
- Kudo P, Dainty K, Clarfield M, Coughlin L, Lavoie P, Lebrun C. Randomized, placebo-controlled, double-blind clinical trial evaluating the treatment of plantar fasciitis with an extracorporeal shockwave therapy (ESWT) device: A North American confirmatory study. *J Orthop Res* 2006;24:115–123.
- Lohrer H, Nauck T, v Dorn-Lange N, Schöll J, Vester JC. Comparison of radial versus focused extracorporeal shock waves in plantar fasciitis using functional measures. *Foot Ankle Int* 2010;31:1–9.
- Padua R, Bondi R, Ceccarelli E, Ripanti S, Bondi L, Campi A. Extracorporeal shock wave therapy for chronic calcifying tendinitis of the shoulder. *J Orthop Traumatol* 2002;2:147–150.
- Hsu CJ, Wang DY, Tseng KF, Fong YC, Hsu HC, Jim YF. Extracorporeal shock wave therapy for calcifying tendinitis of the shoulder. *J Shoulder Elbow Surg* 2008;17:55–59.
- Rompe JD, Zoellner J, Nafe B. Shock wave therapy versus conventional surgery in the treatment of calcifying tendinitis of the shoulder. *Clin Orthop Relat Res* 2001;72–82.
- Vavken P, Holinka J, Rompe JD, Dorotka R. Focused extracorporeal shock wave therapy in calcifying tendinitis of the shoulder: A meta-analysis. *Sports Health* 2009;1:137–144.
- Yao G, Chen J, Duan Y, Chen X. Efficacy of extracorporeal shock wave therapy for lateral epicondylitis: A systematic review and meta-analysis. *Biomed Res Int* 2020;1–8.
- Schaden W, Fischer A, Sailler A. Extracorporeal shock wave therapy of nonunion or delayed osseous union. *Clin Orthop Relat Res* 2001:90–94.
- Eslamian F, Shakouri SK, Jahanjoo F, Hajjaliloo M, Notghi F. Extra corporeal shock wave therapy versus local corticosteroid injection in the treatment of chronic plantar fasciitis, a single blinded randomized clinical trial. *Pain Med* 2016;17:1722–1731.
- Lai TW, Ma HL, Lee MS, Chen PM, Ku MC. Ultrasonography and clinical outcome comparison of extracorporeal shock wave therapy and corticosteroid injections for chronic plantar fasciitis: A randomized controlled trial. *J Musculoskelet Neuronal Interact* 2018;18:47–54.
- Purcell RL, Schroeder IG, Keeling LE, Formby PM, Eckel TT, Shawen SB. Clinical outcomes after extracorporeal shock wave therapy for chronic plantar fasciitis in a predominantly active duty population. *J Foot Ankle Surg* 2018;57:654–657.
- Gollwitzer H, Diehl P, von Korff A, Rahlfs VW, Gerdesmeyer L. Extracorporeal shock wave therapy for chronic painful heel syndrome: A Prospective, double blind, randomized trial assessing the efficacy of a new electromagnetic shock wave device. *J Foot Ankle Surg* 2007;46:348–357.
- Wang CJ. Extracorporeal shockwave therapy in musculoskeletal disorders. *J Orthop Surg Res* 2012;7:11.

34. Cleveland RO, v Chitnis P, McClure SR. Acoustic Field of a Ballistic Shock Wave Therapy Device. *Ultrasound Med Biol* 2007;33:1327–1335.
35. Katz JE, Clavijo RI, Rizk P, Ramasamy R. The basic physics of waves, soundwaves, and shockwaves for erectile dysfunction. *Sex Med Rev* 2020;8:100–105.
36. Wang CJ. An overview of shock wave therapy in musculoskeletal disorders. *Chang Gung Med J* 2003;26:220–232.
37. Thiel M, Nieswand M, Dörffel M. The use of shock waves in medicine—a tool of the modern OR: An overview of basic physical principles, history and research. *Minim Invasive Ther Allied Technol* 2000;9:247–253.
38. van der Jagt OP, van der Linden JC, Schaden W, van Schie HT, Piscaer TM, Verhaar JA, Weinans H, Waarsing JH. Unfocused extracorporeal shock wave therapy as potential treatment for osteoporosis. *J Orthop Res* 2009;27:1528–1533.
39. d'Agostino MC, Craig K, Tibalt E, Respizzi S. Shock wave as biological therapeutic tool: From mechanical stimulation to recovery and healing, through mechanotransduction. *Int J Surg* 2015;24(Pt B):147–153.
40. Cheng JH, Wang CJ. Biological mechanism of shockwave in bone. *Int J Surg* 2015;24 (Pt B):143–146.
41. Wang N, Tytell JD, Ingber DE. Mechanotransduction at a distance: Mechanically coupling the extracellular matrix with the nucleus. *Nat Rev Mol Cell Biol* 2009;10:75–82.
42. Jaalouk DE, Lammerding J. Mechanotransduction gone awry. *Nat Rev Mol Cell Biol* 2009;10:63–73.
43. Holfeld J, Tepeköylü C, Kozaryn R, Urbschat A, Zacharowski K, Grimm M, Paulus P. Shockwave therapy differentially stimulates endothelial cells: implications on the control of inflammation via toll-like Receptor 3. *Inflammation* 2014;37:65–70.
44. Zhang J, Nie D, Rocha JL, Hogan MV, Wang JH. Characterization of the structure, cells, and cellular mechanobiological response of human plantar fascia. *J Tissue Eng* 2018.
45. Nahlieli O. Extracorporeal lithotripsy. *Atlas Oral Maxillofac Surg Clin North Am* 2018;26:159–167.
46. Shrivastava SK. Shock wave treatment in medicine. *J Biosci* 2005;30:269–275.
47. Lawler AC, Ghiraldi EM, Tong C, Friedlander JL. Extracorporeal shock wave therapy: Current perspectives and future directions. *Curr Urol Rep* 2017;18:25.
48. Valchanou VD, Michailov P. High energy shock waves in the treatment of delayed and nonunion of fractures. *Int Orthop* 1991;15:181–184.
49. Gollwitzer H, Saxena A, DiDomenico LA, Galli L, Bouché RYT, Caminear DS, Fullem B, Vester JC, Horn C, Banke JJ, Burgkart R, Gerdesmeyer L. Clinically relevant effectiveness of focused extracorporeal shock wave therapy in the treatment of chronic plantar fasciitis: A randomized, controlled multicenter study. *J Bone Joint Surg Am* 2015; 97:701–708.
50. Porter MD, Shadbolt B. Intralesional corticosteroid injection versus extracorporeal shock wave therapy for plantar fasciopathy. *Clin J Sport Med* 2005;15:119–124.
51. Cinar E, Saxena S, Uygur F. Combination therapy versus exercise and orthotic support in the management of pain in plantar fasciitis: A randomized controlled trial. *Foot Ank Int* 2018;39:406–414.
52. Antonic V, Mittermayr R, Schaden W, Stojadinovic A. Evidence supporting extracorporeal shock wave therapy for acute and chronic soft tissue wounds. *Wounds* 2011; 23:204–215.
53. Mittermayr R, Antonic V, Hartinger J, Kaufmann H, Redl TL, Stojadinovic A, Schaden W. Extracorporeal shock wave therapy (ESWT) for wound healing: Technology, mechanisms, and clinical efficacy. *Wound Repair Regen* 2012;20:456–465.
54. Buizza A, Dell'Aquila T, Giribona P, Spagno C. The performance of different pressure pulse generators for extracorporeal lithotripsy: A comparison based on commercial lithotripters for kidney stones. *Ultrasound Med Biol* 1995;21:259–272.
55. Schmitz C, Császár NB, Rompe JD, Chaves H, Furia JP. Treatment of chronic plantar fasciopathy with extracorporeal shock waves (review). *J Orthop Surg Res* 2013;8(1):31.
56. Lohrer H, Nauck T, Korakakis V, Malliaropoulos N. Historical ESWT paradigms are overcome: A narrative review. *Biomed Res Int* 2016:1–7.